

Primary Epithelioid Sarcoma of the Neck: A Rare Case Report

Viktoras Rudžianskas¹, Elona Juozaitytė¹, Arturas Inčiūra¹,
Valdas Šarauskas², Milda Rudžianskienė¹

¹Institute of Oncology, Medical Academy, Lithuanian University of Health Sciences,

²Department of Pathological Anatomy, Medical Academy, Lithuanian University of Health Sciences, Lithuania

Key words: sarcoma; head and neck cancer; surgery; brachytherapy.

Summary. This report presents a case of a neck epithelioid sarcoma in a 20-year-old man with poor prognosis. The patient underwent surgery followed by external beam radiotherapy and brachytherapy performed as a boost. The treatment was well-tolerated, and there was no local recurrence or distant metastasis.

Introduction

Epithelioid sarcoma (ES) is a rare and aggressive tumor of soft tissues, which was first described in 1970 by Enzinger (1). ES accounts for <1% of all soft tissue sarcomas; manifestations most frequently occur in the distal upper extremities, while involvement of the head and neck is observed in only 1% of cases (2). The prognosis for patients with soft tissue sarcoma (STS) is associated with patients' age, tumor size, histologic grade, and postoperative margin status. Age of more than 60 years, tumor larger than 5 cm, high-grade histology, or positive resection margins are poor prognostic markers, with a high probability of developing a locoregional recurrence or/and distant metastases within the first 2 years (3, 4). To establish the diagnosis, an open biopsy and a detailed immunohistochemical analysis are often required (5). Radical surgical excision is the treatment of choice for STS, and postoperative (adjuvant) radiotherapy is recommended for patients with poor prognosis to improve local control. For this purpose, two methods of radiotherapy – brachytherapy or external beam radiotherapy (EBRT) – or a combination of them are used. The advantage of using EBRT and brachytherapy as a boost is that a higher dose can be delivered directly to the tumor bed, sparing the normal adjacent tissues (6). Brachytherapy catheters are inserted into the tumor bed under direct visualization by a surgeon and an oncologist as parallel as possible at 10- to 15-mm intervals with a security margin of 20 mm in all directions around the target. This report presents a case of ES of the head and neck belonging to a poor-prognosis group with difficulties regarding diagnostic and treatment options.

Case Report

A 20-year-old man was admitted to the Clinic

of Maxillofacial Surgery, Hospital of Lithuanian University of Health Sciences. The patient had been complaining of pain in the right side of the neck, where the mass was located, for 3 months. The patient was a nonsmoker and an abstainer.

On examination, a 4×3-cm fixed, nontender mass was palpable in the patient's right side of the neck. Further physical examination including nasopharyngoscopy and laryngoscopy revealed no pathological findings.

CT showed a 30×35-mm heterogeneous mass in the right submandibular region with central necrosis. The mass caused dislocation of the right common carotid artery and internal jugular vein (Fig. 1). X-rays of the thorax and ultrasound of the abdomen did not reveal any metastasis in the internal organs.

A fine-needle biopsy was performed for diagnostic purposes, which confirmed malignant lesions, but this was not sufficient to establish the diagnosis of ES. An open biopsy was performed by a surgeon, and histopathological investigation of the biopsy sample showed extensive necrosis and myxoid changes, and a proliferation of epithelioid cells with eosinophilic cytoplasm and atypical spindle cells (Fig. 2). Immunohistochemical staining was definitive and positive for cytokeratin 18 (CK-18), carcinoembryonic antigen 1 (CEA-1), vimentin, and epithelial membrane antigen (EMA). Staining for CK-7, CK-5, CD31, CD34, CD117, CD56, actin, desmin, CD99, CD30, Bcl-2, and S-100 was negative. These findings were sufficient and confirmed the diagnosis of ES.

Magnetic resonance imaging (MRI) was performed to evaluate soft tissue infiltration. A large heterogeneous mass was detected in the right side of the neck in the deep soft tissue under the sternocleidomastoid muscle, which extended from the medial part of the parotid gland to the submandibular region and spread along the posterior margin of the submandibular gland, circulating anterolaterally around the internal and external carotid arter-

Correspondence to V. Rudžianskas, Institute of Oncology, Medical Academy, Lithuanian University of Health Sciences, Eivenių 2, 50028 Kaunas, Lithuania
E-mail: viktoras@hotmail.com

ies, and involved the upper margin of the larynx, measuring 25×55×90 mm. Enlarged lymph nodes were observed: levels IA and IIA on both sides and level IB on the right side. The internal jugular vein was invisible in the conglomerate of lymph nodes. No infiltration and deformation of the larynx and pharynx were observed (Figs. 3A and 3B). Computed tomography (CT) of the chest and abdomen revealed no pathological findings.

Surgical resection of the tumor was performed through grossly normal tissue planes accompanied by selective lymphadenectomy (lymph nodes, levels I, II, and III, on both sides), and plastic catheters for brachytherapy were placed in the tumor bed. Histological and immunohistochemical analysis reconfirmed the diagnosis of ES. Histologically, no safety margin was obtained, and no metastases in the lymph nodes were detected. After surgical resection, high-dose rate (HDR) brachytherapy (as a boost) and EBRT were administered. The brachytherapy regimen was to deliver 21 Gy in 7 twice-daily (b.i.d.) fractions with a 6-hour minimum interfraction interval (Fig. 4). EBRT (50 Gy in 25 fractions) was administered one week after HDR brachytherapy. Follow-up examination using MRI of the head and neck and CT of the chest and abdomen revealed no local recurrence or distant metastases within the period of 2 years.

Discussion

ES is a mesenchymal tumor with a predominant epithelial differentiation and is positive for mesenchymal and epithelial markers (2, 7). Microscopically, the diagnosis of ES is difficult to establish, as this tumor has many histologic mimics including malignant fibrous histiocytoma, nodular fasciitis, synovial sarcoma, chronic granulomatous, metastatic squamous cell carcinoma, metastatic adenocarcinoma, amelanotic melanoma, and malignant rhabdoid tumors of the soft tissue (1, 2, 7). ES is characterized by a nodular proliferation of uniform, polygonal, or epithelioid cells with eosinophilic cytoplasm and pleomorphic nuclei with occasional mitoses. Central necrosis and ulceration are typical, and calcification, osseous metaplasia, or myxoid changes are observed (2, 7).

To establish the diagnosis of ES, fine-needle aspiration biopsy alone is insufficient (5). Often open biopsy is needed, and further histological investigation and immunohistochemistry may help diagnose ES. In our case, fine-needle biopsy was informatively insufficient for establishing the diagnosis of ES, and open biopsy was performed. The open biopsy sample revealed histological and immunohistochemical changes typical of ES.

Immunohistochemically, ES shows a high expression of vimentin and, in most cases, is positive

for cytokeratins and EMA (2, 7). Coexpression of cytokeratin and vimentin is observed in the majority of ES cases, but there have been 3 cases described in which the reaction for vimentin was negative and for keratin was positive (8). In more than half of cases, staining for CD34 is positive (2, 7). In some cases, ES is positive for S-100 protein, which is characteristic of a melanoma, but negative staining for HMB45 excludes the diagnosis of melanoma (8). In our case, immunohistochemical analysis showed positive staining for CK-8, vimentin, and EMA, but negative staining for CD34 and S-100.

A wide total surgical excision with clear margins (amputation or wide en bloc excision) is the main treatment modality for ES (2–4, 9, 10). However, wide tumor excision in head and neck sarcomas is difficult to perform, because important anatomical structures (e.g., major vessels and nerves) are located close to each other (6). Lymphadenectomy is indicated in the presence of lymph node metastases (4, 10). Despite the use of radical surgery, this tumor is associated with a high incidence of locoregional failure. Local recurrence often develops within 1 to 2 years after primary treatment (3, 4). Chase and Enzinger reported the results of 202 cases of ES: 77% of the patients had recurrence, and 45% had metastasis to lungs (51%), lymph nodes (34%), scalp and other skin areas (22%), bone, brain, liver, and pleura (2). Other authors reported the local recurrence rate varying from 35% to 50% and the distant metastasis rate varying from 7% to 42% (3, 4).

Gender, margin status, and tumor size are prognostic factors. In multiple studies, female patients showed a more favorable outcome. Most authors reported that local recurrence and low overall survival were associated with tumor size, specifically >5 cm, and positive surgical margins (1–4, 9, 10). The results of 2 studies in the literature showed that the local recurrence rates after radical resection (R0) were 12% and 10%, respectively, and after nonradical resection (R1), these rates were 60% and 36%, respectively (9).

Adjuvant postoperative radiation therapy is recommended if the surgical margin is not satisfactory or the histology of the lesion is high-grade. To improve local control, adjuvant brachytherapy can be used for the treatment of high-grade sarcomas (6). Callister et al. treated 24 patients with non-metastatic ES with surgery and radiotherapy. The 5-year overall, disease-free, and metastasis-free survival rate was 79% vs. 25%, 51% vs. 13%, and 79% vs. 13%, respectively, for lesion size ≤5 vs. >5 cm, with a complication rate of 20% (9). Some authors reported that a radiation dose of >64 Gy was associated with improved local control, and major complications were associated with a dose of >68 Gy (10).

Adjuvant chemotherapy is indicated for patients

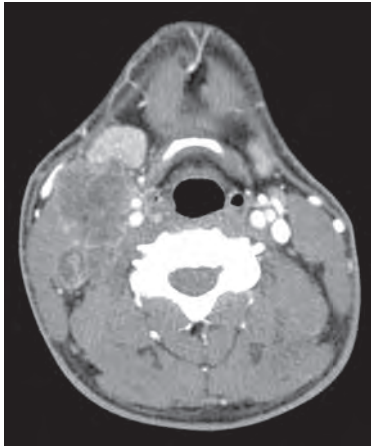


Fig. 1. An enhanced axial computed tomography scan showing a heterogeneous mass in the right submandibular region with central necrosis

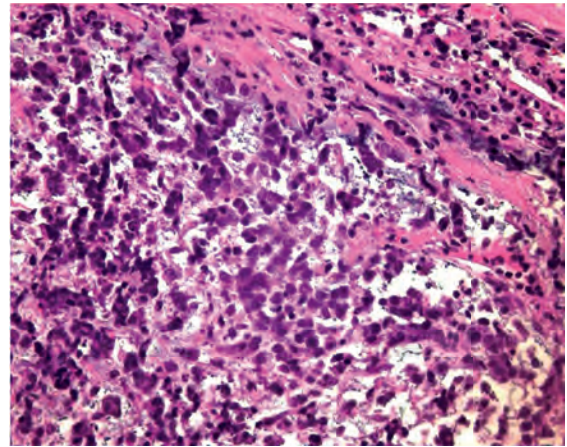


Fig. 2. A microscopic view demonstrating polygonal cells with a moderate amount of cytoplasm and one or several eosinophilic nucleoli in the myxoid stroma
Hematoxylin-eosin, original magnification $\times 100$.

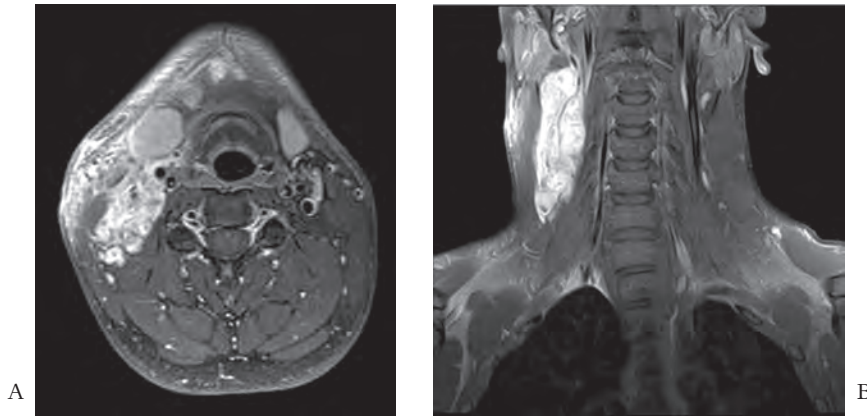


Fig. 3. Axial (A) and coronal (B) T1-weighted, gadobutrol-enhanced magnetic resonance images showing an enhancing mass, which invades internal and external carotid arteries anterolaterally; the internal jugular vein was invisible

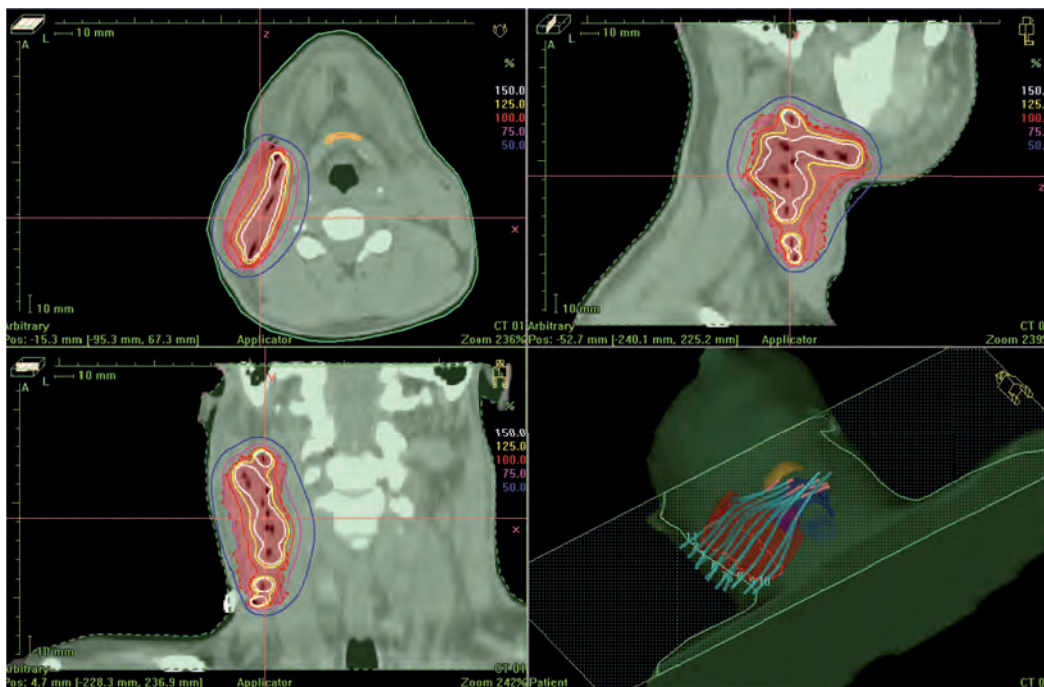


Fig. 4. High-dose rate brachytherapy was planned using Oncentra Master Plan

with metastatic disease, but its usefulness in non-metastatic ES remains unclear (2, 3).

The results discussed above suggest that immunohistochemical analysis is important for the differential diagnosis, and a combination of surgery and radiotherapy is the optimal treatment for head and neck ES.

Our patient underwent tumor excision and selective lymphadenectomy. The patient was in the poor-prognosis group: male sex, surgical margins were not satisfactory, the tumor was larger than 5 cm, and according to the literature, there was a high probability of developing a locoregional recurrence or/and distant metastases within the first 2 years. Due to these findings, postoperative radiotherapy – HDR brachytherapy as a boost in combination with EBRT – were applied to escalate the dose in the tumor bed and to minimize the volume of normal tissues affected by high-dose radiation. The treatment

was well-tolerated: grade 2 acute dermatitis according to the common toxicity criteria of the Radiation Therapy Oncology Group (RTOG) was observed, and no late side effects occurred. After two years, the patient had neither recurrence nor late toxicity, and the quality of his life was reported to be good.

Conclusions

Surgery and radiotherapy (high-dose rate brachytherapy plus external beam radiotherapy) was used for the treatment of epithelioid sarcoma with poor prognosis. No local recurrence and distant metastases were detected after the 2-year follow-up. Local acute toxicity of the treatment was well-tolerated, and no late side effects were observed.

Statement of Conflict of Interest

The authors state no conflict of interest.

References

1. Enzinger FM. Epithelioid sarcoma. A sarcoma simulating a granuloma or a carcinoma. *Cancer* 1970;26:1029-41.
2. Chase DR, Enzinger FM. Epithelioid sarcoma. Diagnosis, prognostic indicators, and treatment. *Am J Surg Pathol* 1985; 9:241-63.
3. de Visscher SAHJ, Ginkel RJ, Wobbles T, Veth RPH, Heuvel SE, Suurmeijer AJH, et al. Epithelioid sarcoma: still an only surgically curable disease. *Cancer* 2006;107:606-12.
4. Singh RP, Grimer RJ, Bhujel N, Carter SR, Tillman RM, Abudu A. Adult head and neck soft tissue sarcomas: treatment and outcome. *Sarcoma* 2008;2008:654987.
5. Goswitz JJ, Kappel T, Klingaman K. Fine-needle aspiration of epithelioid sarcoma. *Diagn Cytopathol* 1993;9:677-81.
6. de Bree R, van der Waal I, de Bree E, Leemans CR. Management of adult soft tissue sarcomas of the head and neck. *Oral Oncol* 2010;46:786-90.
7. Miettinen M, Fanburg-Smith JC, Virolainen M, Shmookler BM, Fetsch JF. Epithelioid sarcoma: an immunohistochemical analysis of 112 classical and variant cases and a discussion of the differential diagnosis. *Hum Pathol* 1999;30:934-42.
8. Arber DA, Kandalaf PL, Mehta P, Battifora H. Vimentin-negative epithelioid sarcoma. The value of an immunohistochemical panel that includes CD34. *Am J Surg Pathol* 1993;17:302-7.
9. Callister MD, Ballo MT, Pisters PWT, Patel SR, Feig BW, Pollock RE, et al. Epithelioid sarcoma: results of conservative surgery and radiotherapy. *Int J Radiat Oncol Biol Phys* 2001;51:384-91.
10. Laney TF, Kepka L, Goldberg SI, Hornicken FJ, Gebhardt, Yoon SS, et al. Radiation therapy for control of soft-tissue sarcomas resected with positive margins. *Int J Radiat Oncol Biol Phys* 2007;67:1460-7.

Received 23 May 2011, accepted 30 January 2012